



THE EFFECT STUDY OF ADDING EXTRACTS OF SOME MEDICINAL PLANTS IN THE BLOODY, SEROLOGICAL AND HISTOLOGICAL CHANGES OF *EIMERIA NECATRIX* AND COMPARED WITH AMPROLIUM IN BROILER CHICKENS ROSS 308

*Thaer Abdelqader Salih *Suad Shallal Shahatha and **Abdulkhaliq Alwan

*Iraq/University of Anbar / College of Science / Department of Biology

**Iraq/TikritUniversity / College of Education / Department of Biology

Thaerparasit@yahoo.com

Abstract

Isolation of the parasite *Eimeria necatrix* locally was applied by taking the area of the center of the intestines and the two cases by 678 samples of massacres of chickens in the city of Ramadi. After purification and exudation outside, the organism was diagnosed through the shape and size of the parasite and the area of infection. The diagnosis of the sample was confirmed in the diagnostic laboratory of disease at the Faculty of Medicine, University of Baghdad. Then, the plant samples were collected and diagnosed in the Faculty of Science-University of Baghdad. The powders were mixed with drinking water and used with the treatment of sulfuric acid, control positive and negative comparison. The samples were infested to the parasite by 5000 Oocysts / bird. The plant powder and water were given to the old chicks the first day at a concentration of 20 mg/ml. Where, they were given three doses a week, after studying the characteristics of production performance and the characteristics of puppet, serological and ionic of all transactions. However, the study of the histological sections in birds of the transactions and found that the best results were in the treatment of pomegranates in terms of therapeutic efficiency and return to normal and reduce the quantity of oocysts parasite and the lowest therapeutic responses were in gum treatments, which remained treatment levels, low efficiency and improved bird level compared with positive and negative control and treatment of amprolium.

Keywords: Medicinal plants, Bloody, serological, *Eimeria necatrix*

Introduction

Avian Coccidiosis Infectious intestinal diseases caused by many parasites division of Apicomplexan the *Eimeria* parasites, a single cell parasite (Duk *et al.*, 2013). In recent decades, there has been a marked increase in the consumption of high quantities of broiler in the world, Which leads to the development of techniques used in production of broiler and the early slaughter of chickens during a record period .In addition to a significant increase in the productivity of breeds, even in the technical boom did not abandon the process of raising poultry from intestinal disorders and deadly diseases of chickens and Leading to reduced production efficiency and the disbursement of excessive amounts of coccidiosis (Luciana da *et al.*, 2014).

Coccidiosis causes high economic loss in the poultry industry due to reduce food conversion and delay growth due to parasite destruction of intestinal epithelial cells. The immune response of the host against coccidiosis is very complex, (Duk *et al.*, 2013) because of the chemical treatments of sulfur compounds against coccidiosis Poultry. As a result of the cumulative effects of these compounds in the consumption of chicken tissues and meat, the world has resorted to alternative plans of treatment as dietary supplements or treatments better than chemical compounds manufactured, so the world went to use safer treatments using plants (Tarek *et al.*, 2016). Several recent studies indicated the possibility of using some of these plants to improve the immunological, physiological and productive properties of farm animals. Some of these plants have already received more attention than medicinal grasses. Their uses have expanded from environmental treatments through food industries to animal feed (2015 ، الامين), in addition to stimulating the functions of the digestive system by increasing the production of digestive enzymes and enhance the effectiveness of the liver and pancreas and small intestine and the formation of bile and secretions, and it helps to

reduce blood lipid levels and improve the immune situation (Shengchen, 2013).

Therefore, a group of medicinal plants were tested for dietary supplements and therapeutic and for measuring some of the physiological and textile factors. Furthermore, they were tested for the production performance of the Ross 308 meat broilers for their knowledge of the role of these plants in future mixing with the diet and reducing the cost of feed and added vitamins. The medically important plants start with gum leaves *Vachellia nilotica*. It contains tannines and preservatives Tannines and it is used to treat diarrhea and dysentery (Zahid *et al.*, 2012). *Punica granatum*, containing polyphenols, is found in high quantities and is an important source of fiber, sugars and pectin. It also comprises estrogen and bonicotanic acid-gallic-manate-biliterin-methyl isobyliterin (Qunqun *et al.*, 2017). Followed by plant root of *Rheum ribes* contains many medicinal substances such as anthraquinoneschrysophanol, parietin and emodin, flavonoids quercetin, fisetin, quercetin 3-0-rhamnoside, quercetin 3-0-galactoside and quercetin 3-0-rutinoside (Ali *et al.*, 2017). Furthermore, the leaves and flowers of the plant *Astragalus mossulensis* contains sesquiterpene-flavonolic complexes, sterols, lignans, coumarins, and phenolic acids.Three toxic groups of phytoconstituents-indolizidine alkaloids, aliphatic nitro compounds, and iron-selenium derivatives (Viktor *et al.*, 2016). The roots of *Astragalus kofensis Velen.* contains the following effective compounds:asparagine, calycosin, formononetin, astragalosides, kumatakenin, sterols, saponins, flavonoids, polysaccharides and glycosides (Xiaoxia *et al.*, 2014).

Materials and Methods

Local isolation of *E. necatrix* obtained from different locations in Anbar governorate and used by 678 samples. Sample collection was started from 1-8-2016 until 28-9-2016 by taking the intestines and cecum, and examining them for possible. Oocysts were prepared for the parasite as

mentioned by Edagar (1955). Methods for preparation, purification and sterilization of Oocytes were based on what came in (Jeffers, 1978). After calculation of Oocysts as stated in (Al-Attar, 1981). Then, Oocytes were examined as reported by Amer *et al.* (2010), where using the microscope and the graduated Ocular Micrometer the diagnosis was confirmed of isolates in Laboratory of Pathological Diagnoses at the Faculty of Veterinary Medicine \ University of Baghdad. The researchers' method that used by Morehouse and Baron (1970) was also used to calculate the lowest dose of Oocytes to cause 50% mortality.

Plant models were collected in the period from 1/10/2016 to 20/12/2016 from different areas of Anbar province, west of the Iraqi capital, Baghdad. The study was conducted in one of biology department halls- Faculty of Science / Anbar University starting from Sunday 1/1/2017 until Saturday 11/2/2017 (42 days). The Ross 308 was caged in cages (100 cm long x 75 cm Width x 50 cm high) in the education hall, provided with water, food, some vitamins and minerals free of charge. The method steps were performed in different periods of lighting times per day (the first 10 days 22 hours lighting, the last 15 hours lighting).

One feed was prepared for all the treatments during the experiment. The preparation of the feed was arranged by specialists at the Upper Euphrates Center for Agricultural Research / Western Region / Branch II. The diet consisted of three types (the first day to the age of 11 days), growth (12-22 days) and the final (from 23 to the end of the experiment). The imported vegetable protein concentrates were used with the diet free of coccidian antacids.

The experiment was designed using 144 broiler chickens (Ross 308) for the experiment. The chicks were taken at the age of the first day and cooked until they were slaughtered at the age of 42 days. Then, eight treatments were used (5 plant treatments + the treatment of the amprolium chemotherapy given with water + Negative control non parasitic infections and without treatments + Positive control parasitic infections and without treatments). Each treatment with 18 chickens was divided into three replicates, each replicate 6 chicken, and the first time was given to the plant powder with water at a concentration of 20 mg / ml and given three doses per week (18 doses). Inoculation of chicks with all vaccines was required (at 2 days of age, the vaccine was given to Newcastle infectious bronchitis IB (by coarse spray), at 9 days old Newcastle (by coarse spray and drinking water), at 14 days (By drinking water) Gambaro and Leukard strains, age 17 days Infectious bronchitis IB (by coarse spray and drinking water), at 19 days Gambaro and Leukard (through drinking water), and finally the vaccine Newcastle (spray) at 23 days .

Characteristics studied

Characteristics of productive performance

All chicks were weighed weekly and individually for each replicate of the experiment and final weights were extracted (the experiment was 42 days) according to the equations presented by (1986, Al-Zubaidi).

The productivity efficiency factor was calculated from the Ross 308 (Ross, 2009) manual.

Losses were recorded and weighed when they occurred and according to the relative growth rate, researchers said (Gondwe and Wollny, 2005).

Hematological Tests

Four birds were killed from each replicate of the experiment (12 birds per treatment). On day 42, the blood collected of each bird was slaughtered in two tubes: the first contains the EDTA for blood tests; the second tube contains no anticoagulant to conduct Biochemical and immunological blood tests, and the tests carried out are:

1. Calculate the total number of white blood cells

Calculated on the Hemacytometer Chamber to find the total number of oocytes, where equation Natt and Herrick (1955) was applied.

2. Calculate the number of red blood cells (cell/mm³)

Calculated on the Hemacytometer to find the total number of red blood cells where equation Natt and Herrick (1955) was applied.

3. Hemoglobin concentration (determination of hemoglobin concentration)

Drabkin was used to estimate the concentration of hemoglobin in the blood sample (Drabkin, and Austin, 1935). The following equation is used: $Hb (g / L) = ABS. X 367.7$

4- Packed cell volume ,erythrocyte sedimentation rate and platelets

The percentage of PCV measured was Hematocrit Reader , Westergene's method was used to Measuring ESR, The Haemocytometer and Ammonium Oxalate 1% were used to calculate platelets (Archer, 1965).

Hematological properties of blood

1. Determination of total protein, albumin and globulin in the serum

The biuret color method was used to determine total protein using Biolinear (Vervelde *et al.*, 1996). And The concentration of albumin was determined according to the enzymatic degradation method of the albumin mentioned (Doumasn and Biggs, 1972) using the prepared estimation kit from the American company Bionerieux. serum globulin concentration after extracting the total protein concentration and albumin as in the following equation (Doumasn and Biggs, 1972). $Serum\ Globulin (g / dl) = S. Albumin (g / dl)$

2 - Determination of the concentration of glucose in the serum

A method Asatoor and King (1954) based on enzymatic decomposition of glucose was used the prepared estimate kit from Bionerieux, USA.

3 - Level determination of total Cholesterol, Triglycerides and HDL in serum

The enzymatic decomposition method was used to estimate total cholesterol level in serum using Bionerieux ready estimate kit (Warnick and Wood , 1995) .

4. Calculate the concentration of (vLDL) and low-density lipoproteins (LDL).

The amount of very low density lipoproteins (vLDL) was calculated using the equation mentioned earlier. Where, LDL was extracted from the equation previously mentioned (Warnick and Wood , 1995) .

5. Determination of AST, ALT and ALP

The efficacy of this enzyme was evaluated in the serum using the colorimetric method. The examination steps were performed according to Randox instructions prepared for this kit, and the samples were read based on (Reitman and Frank *et al.*, 1957).

6- Determination of calcium concentration in the serum

Calcium concentration in serum was measured according to Reitman and Frankel (1957) by Bioleanir kit.

Histological Sections

After taking the tissue sections from the loop area, the installation steps were followed by fixation, washing, dehydration, clearing, infiltration, embedding, sectioning, staining and coloring and eosin Staining Hematoxylin (Bancroft and Stevens, 1975).

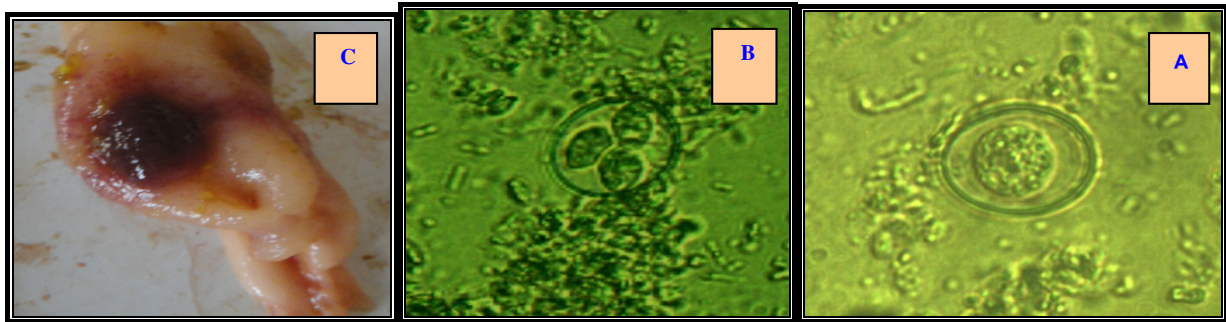


Fig. (1) explain : A} non-mature Oocyst , B} mature Oocyst , C} infected region

Production performance

Table (1) shows that the cumulative performance characteristics of the period 1-42 days have significant differences ($P \geq 0.05$) for the treatment of negative control compared with other treatments. Morphological stability was observed in the production performance of *Punica granatum* and *Astragalus kofensis*, with a significant increase in body weight (2850.6 g) (2055.4 g) and the increase in weight (2532.1 g) (2518.3 g) respectively compared with control Negative and positive chemotherapy and amprolium. It was also shown that there was a significant decrease in the treatment of gum plant for all performance characteristics compared to the treatment of negative and positive control and other factors. The smallest decrease was in this treatment. In addition, there were significant differences in the characteristics of the production performance of the transactions compared to between them and with the treatment of negative control.

It was found that the best coefficients in improving the performance characteristics of the fruit when added with water, calculating the duration of the breeding period, the resistance of the body to diseases and the percentage of losses is the treatment to which the pomegranate powder was added compared to the production characteristics of the other factors and compared with the negative and positive control.

It explained Hosna *et al.* (2011) that the powder of some plants was used at 5 grams per kilo meal as Dietary Supplements for chicken, and this percentage increased the value of production performance when feeding. The immunological indicators and their defensive efficiency were increased when given with the diet and drinking water (as extract) in the granting of positive immunity (Conferring Active Immunity) against diseases. Furthermore, the results showed that this situation may support the immune system and develop the mechanism of defense in the body. Moreover, it reduced the treatment rates of damage and may

Statistical analysis

One way analysis was carried out. The trend included effects of the eight coefficients using the general linear model and the use of the SAS statistical program. Release 9.1 and the moral differences were tested using the Duncun Multiplicity test at a significant level $p \leq (0.05)$ (SAS Institute, 2004).

Results and Discussion

Attributes studied

The smallest amount of oocytes, which gave 50% loss, were 5000 mature oocytes/ per broiler. The parasite size was between $19-23 \mu \times 14-19 \mu$. It was found Eleryet *al.* (1956) that *E. necatrix* size ranges between $15.6-23.9 \mu \times 13.9-19.5 \mu$.

be due to the efficiency of pomegranate peel powder *Punica granatum* to the type of active substances which has been widely used in commercial medical treatments for treatment cases miscellaneous diseases. Where, it contains tannins as materials tanner the gut as well as being an antioxidant, which added a vital role in inhibiting the growth of pathogenic bacteria (Shazia *et al.*, 2018).

It also confirmed Mithun *et al.* (2010) that the provision of extracts of some plant powders, including pomegranate powder to birds, provides protection against fungal diseases and helps to reduce and gradually reduce the severity of diseases. It supports the active immunity in the body, which strengthens the immunity of birds and helps them to get rid of diseases. In addition, it helps to rebuild the tissue, which positively affects the productive performance of the bird.

It was also observed in Table (1) that there was a significant decrease ($P \geq 0.05$) in the treatment of *Vachellia nilotica* in terms of body weight, rate of weight increase, total feed consumption rate, food conversion coefficient and efficiency factor compared to negative control and positive. The study Ogbe and John (2012) showed that there are immunological and production performance changes of chickens and bloody properties when giving the powders of some plants, including gum Arabic, which appear on the bird. It has been shown that the introduction of these extracts did not significantly affect the characteristics of the bird and other organs with control. As explain to the treatment of Arabic gum has a simple negative impact on the productive performance thus to affect body weight and causes low food conversion factor. Furthermore, the lack of full utilization of feed proteins that contribute to the conversion of food into energy utilized in the body construction and growth processes.

Hematological Tests

From the table (2), it can be shown that there are significant differences between the treatment plant *Punica*

granatum compared to positive control. The blood properties in the treatment of peel pomegranate continuous improvement in experience end, as shown that the blood ratios at full characteristics of this treatment close with blood ratios for negative control treatment. The results became clear to document the significant increase and some blood indicators the necessary to deliver complete of food to different body cells and that plant treatment *Punica granatum* played an active role in the increase of the amount of Hb, RBC and Platelet and low percentage of ESR, compared to positive control and rest of transactions Other.

While ranged from others treatment in the proportions among themselves and positive, negative control. Where, *Vachellia nilotica* treatment showed more significant decrease in full blood characteristics, compared to other plants and with positive and negative control too.

The study Mohammed (2013) tested five different plant extracts, including *Punica granatum* extract that were measured at a concentration of 300 mg / kg for 5 days. The researcher showed that there are clear bloody and tissue changes between control and plant treatments. The addition of the extracts changed bloody characteristics. The extracts are antioxidants and anticoccidiosis, and these plants significantly increase the immunological properties and improve some of bloody characteristics. However, some other plants are changing the bloody characteristics to the significant decline.

He reported Elagib and Ahmed (2011) that his study was conducted on 30 adult male chickens and 30 adult female chickens for 56 days, and found that there were changes in the blood (PCV, Hb, RBC, MCV, MCHC, WBC, and MCH), Cholesterol, and Triglycerides. In addition, some plant extracts were limited between significant increase and decrease in ($P \geq 0.05$). This was attributed to the type of active substances in the plants, and the females were more sensitive to the extracts for males.

Serological tests

It was found that the most significant treatment in all serological tests, was the treatment of pomegranate. The least significant treatment was gum Arabic in all its serological characteristics in terms of return to normal ratio compared to

negative and positive control and the treatment of Amprolium and other treatments (Seetables (3) and (4)). A study conducted by Bruno *et al.* (2014) showed that pomegranate powder increased the amount of oocysts that raised to the infected chickens with three types of *Eimeria*. Then, the birds started to heal and the number of oocysts raised with the spit increased (See Table (5)). In addition, another research paper by Elagib and Ahmed (2011) reported that the use of some plants as dietary supplements for chickens for 44 days has increased the value of the serological variables (cholesterol, triglyceride) in nutrition and has increased immunological indicators and defense efficiency when given with the diet. While Piotrowska *et al.* (2011) showed that during the period of incubation and the period of obesity for 14-42 days, a significant increase (total protein, albumins, uric acid, creatinine), lipid TG, TCHL, HDL, mineral (Ca, P (i), Mg, Fe) and that giving some natural extracts of plants, has led to a significant stability in the proportions of these serum and ionic standards. The researchers said that these plants are food supplements and antioxidants help the chickens to get rid of free radicals and metabolic processes harmful or overcome or help the immune system to keep pace with changes in the body. Thus maintain the process of increase the weight of the organism in its ideal form (Jebasingh *et al.*, 2012).

Ionic changes

There was a significant correlation between the glucose amount and the calcium amount in blood in *punica* treatment compared to negative and positive control and Amprolium treatment. Furthermore, it was the best significant treatments (See Table (4)). Several studied Piotrowska *et al.* (2011); Elagib and Ahmed (2011); (Jebasingh *et al.*, 2012); Onukwo and Ugwuene (2015) indicated that the addition of powder of some plants, including pomegranate plant, significantly increased the necessary sugars in energy consumption, metabolic processes, and the conversion of materials into energy for use by cells in feeding and disposal processes. Excess calcium, and added that the proportion of calcium rose in Luhmann chicken to bones strengthen as well as the formation of egg shell, which helps to maintain the egg content.

Table 1 : The characteristics of the production performance and the moral level of 1-42 days (Cumulative) of the experiment

Productive efficiency factor	Relative growth rate (%)	Mortality percentage (%)	Food conversion coefficient Gm feed / Increase in weight	Total feed consumption gm/6 week	Increase in weight (gram)	Rate of body weight (gram)	Treatments
300.77 A	181.24 A	0 A	1.53 A	3640.2 A	2422.2 A	2570.8 A	Negative Control
173.33 B	121.33 B	0.333333 B	1.40 B	3655.2 A	1455.1 B	1551.6 B	Positive Control
294.19 A	180.16 A	0.166667 B	1.58 A	3644.5 A	1622.1 B	1730.5 C	<i>Vachellia nilotica</i>
303.33 A	181.33 A	0 A	1.50 A	3655.2 A	2441.1 A	2550.6 A	<i>Punica granatum</i>
285.24 A	182.21 A	0.333333 B	1.73 AC	3623.1 A	2532.2 A	2625.2 A	<i>Rheum ribes</i>
288.23 A	184.33 A	0 A	1.80 AC	3411.6 A	2455.8 A	2576.2 A	<i>Astragalus mossulensis</i>
263.32 A	182.54 A	0 A	1.69 AC	3673.4 A	2518.3 A	2655.4 A	<i>Astragalus kofensis</i>
301.34 A	181.31 A	0 A	1.52 A	3501.3 A	2699.2 A	2810.3 AC	Amprolium
7.12	3.003	0.0001	0.023	141.90	34.21	23.43	Average standard error
276.2188	174.3063	0.104167	1.59375	3600.5625	2268.25	2383.825	Mean
0.001	0.047	0.012	0.002	0.05	0.025	0.004	Significant level

*The different characters within the same column indicate significant differences between the coefficients at a significant level of 0.05

Table 2 : Heamatological tests in treatment

ESR mm/hr	Platelet Cell/ml	RBC Cell/ml	WBC Cell/ml	PCV %	Hb mg/dl	Treatments
3.40 A	35212 A	3510000 A	17723.1 A	35.20 A	11.32 A	Negative Control
9.18 B	21734 B	2724519 B	23111.2 B	21.05 B	6.13 B	Positive Control
4.32 A	30001 AC	3128271 AC	16745.9 AC	30.61 AC	10.12 A	<i>Vachellia nilotica</i>
3.12 A	35217 A	3510021 A	17742.4 A	36.15 A	12.13 AC	<i>Punica granatum</i>
4.82 A	30199 AC	3222081 AC	18021.8 A	31.14 AC	10.34 A	<i>Rheum ribes</i>
2.13 C	35006 A	3762918 A	18092.1 A	34.91 A	11.26 AC	<i>Astragalus mossulensis</i>
2.29 C	32291 AC	3298764 AC	18902.3 A	35.30 A	11.08 A	<i>Astragalus kofensis</i>
3.89 A	35345 A	3528912 A	17639.3 A	35.24 A	11.59 AC	<i>Amprolium</i>
0.839	1792.3	152831.1	233.0	1.38	0.56	Average standard error
3.6575	27457.5	2894571.75	16292.35	28.42	9.1725	Mean
0.041	0.032	0.004	0.029	0.009	Less than 0.00001	Significant level

*The different characters within the same Colum indicate significant differences between the coefficients at a significant level of 0.05

Table 3 : Serological tests in treatments

Lipids					Liver enzymes			proteins			Treatments
vLDL mg/dl	Triglyceride mg/dl	LDL mg/dl	HDL mg/dl	Cholesterol mg/dl	ALP U/dl	GOT (AST) U/dl	GPT (ALT) U/dl	Total Globulin g/100ml	Total Albumin g/100ml	Total Protein g/100ml	
7.3 A	36.5 A	130.0 A	55.1 A	192.4 A	256.7 A	23.6 A	18.12 A	1.0 A	2.7 A	3.7 A	Negative Control
19.0 B	95.0 B	38.7 B	90.4 B	129.1 B	134.9 B	33.2 B	15.23 B	2.4 B	3.5 B	5.9 B	Positive Control
11.14 C	55.7 A	83.56 C	34.8 C	148.5 C	209.2 AC	28.5 AC	18.55 A	0.7 A	2.6 A	3.3 A	<i>Vachellia nilotica</i>
7.0 A	35.0 A	140.7 AD	50.4 A	198.1 A	234.9 A	23.2 A	17.13 A	1.4 A	2.5 A	3.9 A	<i>Punica granatum</i>
9.2 AC	46.0 A	103.6 AE	78.1 AB	190.9 A	198.2 AC	28.5 AC	17.76 A	1.1 A	2.8 A	3.9 A	<i>Rheum ribes</i>
6.9 A	34.7 A	113.16 ACE	69.8 AB	189.9 A	229.3 A	27.5 AC	18.65 A	1.2 A	2.3 A	3.5 A	<i>Astragalus mossulensis</i>
9.0 AC	45.0 A	89.5 C	81.8 AB	180.3 A	224.8 AC	27.5 AC	18.12 A	1.0 A	2.8 A	3.8 A	<i>Astragalus kofensis</i>
7.5 A	37.5 A	136.3 AD	55.3 A	199.1 A	266.4 A	23.9 A	18.20 A	1.1 A	2.8 A	3.7 A	<i>Amprolium</i>
1.7	7.9	14.6	14.5	5.8	13.9	28.8	0.71	0.29	0.25	0.30	Average standard error
9.63	48.175	104.44	64.4625	178.5375	219.3	26.9875	17.72	1.2375	2.75	3.9625	Mean
0.002	0.007	0.012	0.003	0.001	0.003	0.003	0.005	0.04	Less than 0.0001	Less than 0.0001	Significant level

*The different characters within the same Colum indicate significant differences between the coefficients at a significant level of 0.05

Table 4 : Ions treatments

Ions		Treatments
Calcium mg/ L	Glucose mg/dl	
9.43A	203.4 A	Negative Control
6.84B	133.1B	Positive Control
8.12AC	187.3AC	<i>Vachellia nilotica</i>
9.74A	199.1A	<i>Punica granatum</i>
9.16A	171.9AC	<i>Rheum ribes</i>
9.37A	201.2A	<i>Astragalus mossulensis</i>
8.54AC	206.1A	<i>Astragalus kofensis</i>
9.99A	203.8A	Amprolium
0.199	3.160	Average standard error
8.89875	188.2375	Mean
Less than 0.00001	Less than 0.00001	Significant level

*The different characters within the same Colum indicate significant differences between the coefficients at a significant level of 0.05

Table 5 : Total mount oocysts presented with faces (gm/ml)

Experimentation days after giving parasite and give treatment							Treatments
Lesion score	Mean	Twenty	Fifteen	Tenth	fifth	first	
0	0 A	0 A	0 A	0 A	0 A	0 A	Negative Control
+ 3	1172.05B	14890 B	5984 B	2189 B	378 B	0 A	Positive Control
+ 2	284.8C	3300 C	1690 C	580 C	126 C	0 A	<i>Vachellia nilotica</i>
+ 1	20.9A	100 A	100 A	118 A	0 A	0 A	<i>Punica granatum</i>
+ 1	50.8A	412 A	328 A	178 A	98 AC	0 A	<i>Rheum ribes</i>
+ 1	38.8A	312 A	298 A	166 A	0 A	0 A	<i>Astragalus mossulensis</i>
+ 1	40.7A	322 A	282 A	210 A	0 A	0 A	<i>Astragalus kofensis</i>
+ 1	6.6A	24 A	76 A	32 A	0 A	0 A	Amprolium
	0.01	0.05	0.04	0.003	0.021	NS	Significant level

*The different characters within the same Colum indicate significant differences between the coefficients at a significant level of 0.05

Histological changes

At dissection time, the severity of the tissue lesion was clearly found in the middle central intestine and at cecca beginning in the second group (positive control) and the third (gum Arabic) with the different developmental stages of the parasite. Number of gametes were represented the evolutionary stages of the parasite as a result of the parasite invasion of the tissue of cecca. This causes a clear destruction of the mucous and subcutaneous layers (tissue disruptive). This was found in white and yellow dots, and the condition of the vacoulation, thickening of the subcutaneous layer, Figures (2) (3) (4) and (5). While, the treatment of negative control did not show the pathological signs of being uninfected. In addition, after the pathological characteristics of the treatment of currant *Rheum ribes* and *Astragalus mossulensis*, the presence of sporadic stages in the infected tissue but with less stress than the positive control treatment. In addition to the presence of oocysts for the parasite in the tissues, while the best treatment in terms of the tendency to cure the infection is the treatment of *Punica granatum* and *Astragalus kofensis* and amprolium. The treatment of *Punica granatum* was the best in comparison to negative control. The infected chicks were treated with healing and the number of oocysts with faces decreased significantly gradually. However, there is a proliferation of lymphocytes in the tissue (Figure 6). This may be due to the quality of active substances found in pomegranate husks of *Punica granatum* (especially tannins) and polyphenols: ethothianine and hydrolysal Tannines in high quantities. It is also important for fiber, sugars and pectin as it contains estrogen and contains bonicotanic acid-gallic acid - manate - pyliterin - methyl isoblitrin (Qunqun *et al.*, 2017).

The infiltration of lymphocytes with hyperplasia and degeneration of the mucous and subcutaneous layer in all treatments (except for negative control) is evidence that T lymphocytes, which are responsible for cellular immunity, directly affect intracellular spores within the epithelial cells (Lillehoj *et al.*, 2004). Thus, Th1 and Th2 secrete Lymphocytes after interacting with the Ag antigen. These roles have a direct effect on the evolution of the parasite in the early stages of infection and control of antibody production, and the monocytes and heterogeneity have an important effect against the spores of the mucous layer. Therefore, the immune response to the injury depends on the increased concentration of these cells (Yun *et al.*, 2000). Clinical signs, including bloody dysentery caused by the penetration of spores of intestinal and cecca epithelial tissue at the completion of the parasite's life cycle within the body, as shown by Rosa and Edgar (2015) that natural plants nature as antioxidants, food supplements and immunological assistance to control coccidiosis disease rather than chemical treatments is much better in terms of product quality, economic cost and lack of accumulation of chemicals. As a result of treatment within the meat produced, for plant alternatives widely applied in recent times.

Our results are consistent with Jadhav *et al.* (2011), where they showed that *E. necatrix* caused bloody diarrhea and caused loss of weight for the infected bird. As well as poor production efficiency, general weakness, ionic disorder, serological and immune imbalance of the bird, and an imbalance of the free radicals and antioxidants in the body.

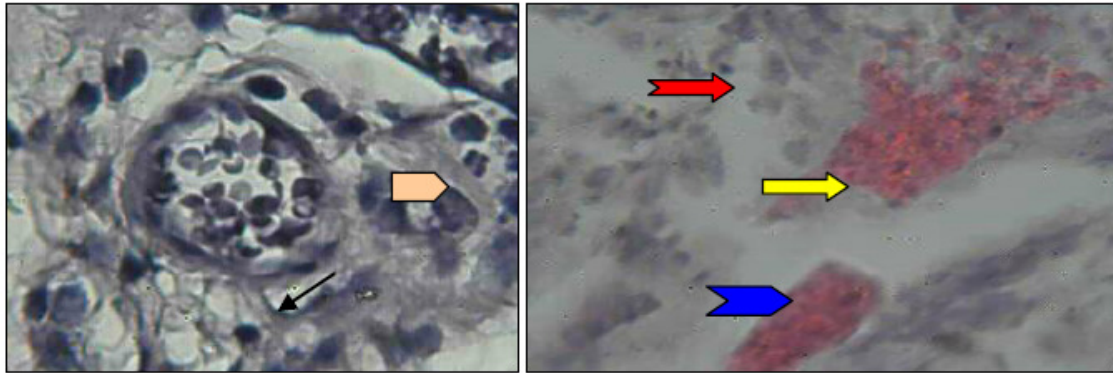


Figure (2) show large schizont (→), and sporozoites (→), vacuolation (→), bleeding and necrosis (→), Oocysts (→). H & E (40 x) stain

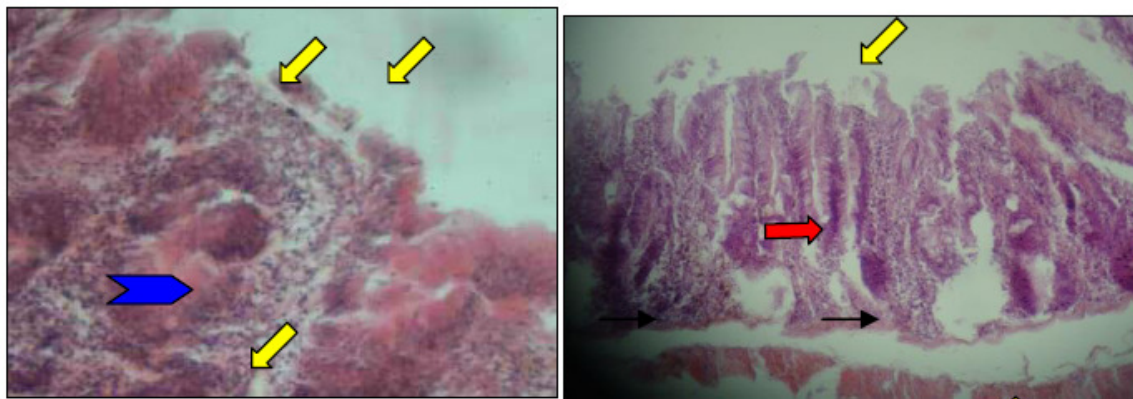


Figure (3) show lymphocytes infiltration (→), subcutaneous rupture (→), vacuolation (→), Bleeding (→). H & E (40 x) stain .

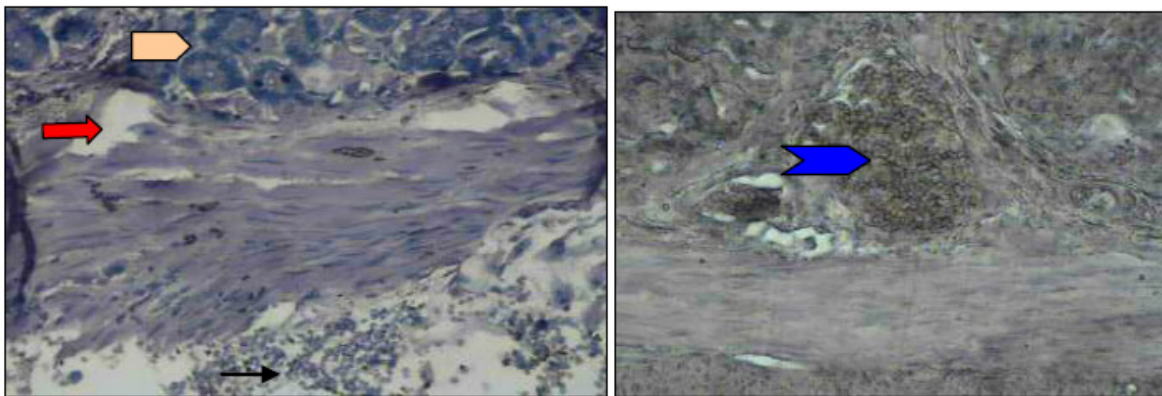


Figure (4) Show lymphocytes infiltration (→), Oocysts (→), Vacuolation (→), Schizonte(→). H & E (40 x) stain .

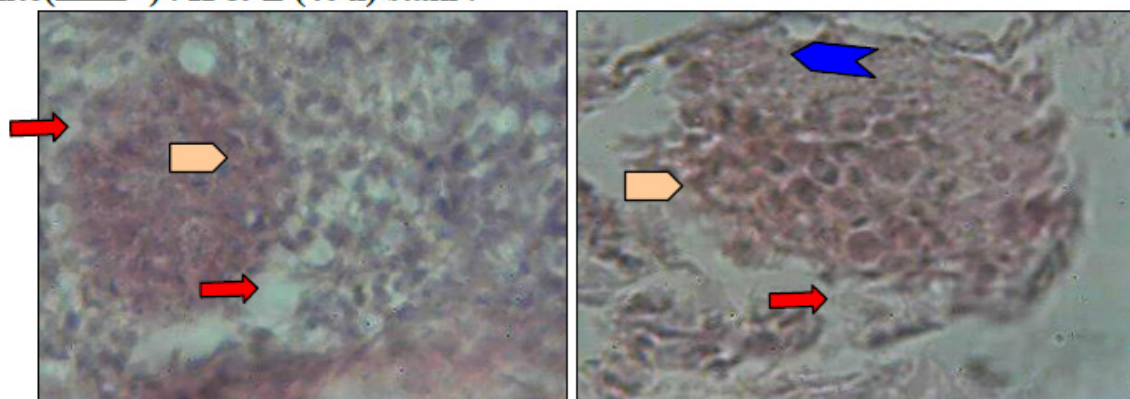


Figure (5) Show Vacuolation(→), Schizonte(→), tissues rupture (→). H & E (40 x) stain

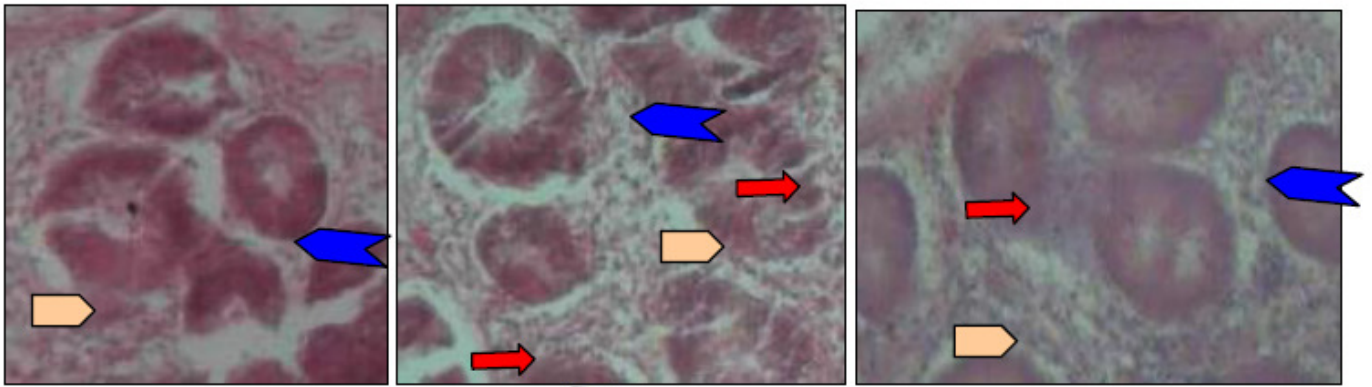





Figure (6) Show Secretion glands(), lymphocytes filtration (), tissues and secretion glands back to the natural state of() . H & E (40 x) stain

Conclusions

- The pomegranate powder of *Punica granatum* was the best treatment in terms of improving the performance characteristics and indicators of the characteristics of the bloody, serological and ionic and the arrangement of the tissues section. While the least significant decrease of the indicators mentioned above is in the powder gum (*Vachellia nilotica*) compared to positive and negative control and treatment of amprolium.
- The rest of the other treatments had mixed effects on the characteristics of the productive performance and the qualities described above.

Recommendations

Mix pomegranate husk powder (*Punica granatum*) with the food or give it with drinking water for the purpose of improving chicken growth and intestinal epithelium tanner and making it more resistant to bacterial and parasitic diseases.

References

- Al-Attar, M.A. (1981). Factors effecting the pathogenesis *Eimeria necatrix* infections in chicken. Ph.D. Thesis University of Guelph. Canada.
- Ali, Kh.; Mohammad, H.; Mehrdad, Sh.; Mohammad, H.; Afsaneh, Sh.; Seid, K.; Zohre, M.; Marzie, J.; Mohammad, K. and Majid, E. (2017). Effects of rhubarb (*Rheum ribes* L.) syrup on dysenteric diarrhea in children: a randomized, double-blind, placebo-controlled trial. *Journal of Integrative Medicine*, 15(5), 365-372.
- Amer, M.M.; Awaad, M.H.H; El-Khateeb, R.M.; Abu-Elezz, N.M.; Said, S.; Ghetas, M.M. and Kutkat, M.A. (2010). Isolation and Identification of *Eimeria* from Field coccidiosis in chickens. *Journal of Amricanscience.*; 6(10).
- Archer, R.K. (1965). *Hematological techniques for use on animals*. Oxford: Blackwell Scientific Publication.
- Asatoor, A. and King, E. (1954). Glucose measurement. *Biochem. J.*, 56(X – IV).
- Bancroft, J. and Stevens, A. (1975). Haematoxylin and eosin and the applications of haematoxylin. In: J.D. Bancroft & A.A. Stevens (eds). *Histopathological stain and their diagnostic uses*. Churchill Livingstone, Edinburgh, London. PP. 1-11.
- Bruno, P.; Helcio, R.; Hata&nderson, L.; Viviane, M.; Walter, F.; Walter, L. and Carlos, W. (2014). Evaluation of

pomegranate (*Punica granatum*) pericarp aqueous extract on *Eimeria* spp. from Japanese quails (*Coturnix japonica*). *International Journal of Veterinary Science and Medicine*, 2(1): 35-40 . Doumasn, B.T. and Biggs, H.G. (1972). Determination of serum albumin-Standard method of clinical chemistry- Acad. Press. N.Y.7 .175-188.

- Drabkin, D.L. and Austin, J.H. (1935). Spectrophotometric Studies: II. Preparations from washed blood cells ; Nitric Oxide Hemoglobin and Sulfhemoglobin. *J. Biol. Chem.*, 112: 51-65.
- Duk, K.; Hyun, S.; Sung, H.; Seung, I.; Erik, P. and David, B. (2013). Dietary *Curcuma longa* enhances resistance against *Eimeria maxima* and *Eimeria necatrix* infections in chickens. *Poultry Science*, 92(10): 2635–2643.
- Edagar, S.A. (1955). Sporulation of oocysts at specific temperatures and notes on the prepatent period of several species of avian coccidiosis. *J. Parasitol.* 41:214-216.
- Elagib, H. and Ahmed, A. (2011). Comparative Study on Haematological Values of Blood of Indigenous Chickens in Sudan. *Asian Journal of Poultry Science*, 5: 41-45.
- Elagib, H. and Ahmed, A. (2011). Comparative Study on Haematological Values of Blood of Indigenous Chickens in Sudan. *Asian Journal of Poultry Science*, 5: 41-45. Elery, R.; Jessen, R.; Walter, H. and Willa, V. (1956). A Biometrical Study of the Oocyst of *Eimeria necatrix*, a Parasite of the Common Fowl. *Eukaryotic Microbio.*, 3(3); 126–131.
- Gondwe, T. and Wollny, C. (2005) . Evaluation of the growth potential of local chickens in Malawi . *Int. J. of Poult. Sci.* 4(2): 64-70.
- Hosna, H.; Ahmad, H. and Park W.W. (2011). Effects of Dietary Supplementation with Pumpkin oil (*Cucurbitapepo*) on Performance and Blood Fat of Broiler Chickens during Finisher Period .*American Journal of Animal and Veterinary Sciences* 6 (1): 40-44
- Jadhav, B.N.; Nikam, S.V.; Bhamre, S.N. and Jaid, E.L. (2011). Study of *Eimeria necatrix* in broiler chicken from Aurangabad district of Maharashtra state India. *International Multidisciplinary Research Journal.* 1(11):11–12.
- Je basingh, D.; Venkataraman, S.; Jackson, D. and Emerald, B. (2012). Physiochemical and toxicological studies of

- the medicinal plant *Cyperus rotundus* L. (Cyperaceae). IJARNP. 5(4): 222-231.
- Jeffers, T.K. (1978). *Eimeria necatrix* sensitivity of recent field isolants to monensin. Avian Dis., 22: 157-161.
- Lillehoj, H.; Min, W. and Dalloul, R. (2004). Recent Progress on the Cytokine Regulation of Intestinal Immune Responses to *Eimeria*. College of Veterinary Medicine, University of Maryland. Poult. Sci. 83: 611–623.
- Luciana da, S.; Elder, N.; Augusta, A.; Vinícius, B.; Costa, S. and Fagner, L. (2014). Experimental Infection with Sporulated Oocysts of *Eimeria maxima* (Apicomplexa: Eimeriidae) in Broiler. Journal of Veterinary Medicine .Volume (2014), Article ID 283029, 7 pages.
- Mithun, B.; Prashant, G.; Murlikrishna, K.; Shivakumar, K. and Chandu, G. (2010). Antifungal efficacy of *Punica granatum*, *Acacia nilotica*, *Cuminumcuminum* and *Foeniculumvulgare* on *Candida albicans*: An *in vitro* and *in vivo* study . Indian Journal of Dental Research, 21(3): 334-336.
- Mohammed, A.D. (2013). Anti-coccidial, anthelmintic and antioxidant activities of pomegranate (*Punica granatum*) peel extract. Parasitology Research. 112(7): 2639–2646.
- Morehouse, N.F. and Baron, R.R. (1970). Coccidiosis: Evaluation of coccidiostats by mortality, weight gains and fecal scores. Exp. Parasitology 28:25-29.
- Natt, M.P and Herrick, C.A. (1955). The effect of coccidiosis on the blood cells of the domestic fowl: A comparison of the changes in the erythrocyte count resulting from haemorrhage in the infected and mechanically bled birds; the use of haematocrit value as an index of the severity of the haemorrhage resulting from the infection. Poult. Sci. 34: 1100-1106.
- Ogbe, A. and John, P. (2012). Effect of Polyherbal Aqueous Extracts (Moringaoleifera, Gum arabic and wild Ganodermalucidum) in Comparison with Antibiotic on Growth Performance and Haematological Parameters of Broiler Chickens. Research Journal of Recent Sciences, 1(7): 10-18.
- Onukwo, D.N. and Ugwuene, M.C. (2015). Growth Performance of Broiler Chicken Fed Varying Levels of Tiger Nut (*Cyperus esculentus* L) Seed meal. International Journal of Livestock Research. 5(2): 78-85.
- Piotrowska, A.; Burlikowska, K. and Szymeczko, R. (2011). Changes in blood chemistry in broiler chickens during the fattening period .Folia Biol (Krakow). 59(3-4):183-7.
- Qunqun, G.; Guicai, D.; Hongtao, Q.; Yanan, Zh.; Ongqing, Y.; Jingchao, W. and Ronggui, L. (2017). A nematicidal tannin from *Punica granatum* L. rind and its physiological effect on pine wood nematode (*Bursaphelenchusxylophilus*) .Pesticide Biochemistry and Physiology. 135: 64-68.
- Reitman, S. and Frankel, S. (1957). Liver enzymes functions measurement. Amer. J. Clin. Path.28:56.
- Rosa, E. and Edgar, D. (2015). Control of Avian Coccidiosis: Future and Present Natural Alternatives. Biomed Res Int., 430610.
- Ross (2009). Broiler management manual of ROSS 308. Aviagen company.
- SAS Institute. (2004). The SAS System for Windows, Release 9.01. SAS Institute Inc., Cary, NC.
- Secretary, K.M. (2015). Effect of adding turmeric powder on the performance of broiler chickens. Khartoum University. Faculty of Production Agricultural sector. Khartoum Press. 320 pages.
- Shazia, A.; Syed, T.; Tauseef, A. and Irshad, A. (2018). Anticoccidial activity of fruit peel of *Punica granatum*L .Microbial Pathogenesis .https://doi.org/10.1016/j.micpath.2018.01.015 .
- Shengchen, Su. (2013). Expression of Digestive Enzymes and Nutrient Transporters in the Intestine of *Eimeria* -challenged Chickens. Thesis Master of Science . Animal and Poultry Sciences. 74pp.
- Tarek, A.; Bassant, A. and Laila, H. (2016). Development of immunization trials against *Eimeria* spp. Trials in Vaccinology, 5: 38–47.
- Vervelde, L.; Vermeulen, A. and Jeurissen, S. (1996). Characterization of leukocyte sub populations involved in immunity after infection with *Eimeria necatrix* in chicken's parasite. Immunol. 18: 247-256.
- Viktor, M.; Aleksandar, M.; Petranka, K. and Iilina, N. (2016). Flavonoids from the Genus *Astragalus*: Phytochemistry and Biological Activity. Pharmacogn Rev. 10(19): 11–32.
- Warnick, G.R. and Wood, P.D. (1995). National Cholesterol Education Program recommendations for measurement of high-density lipoprotein cholesterol: executive summary. Clin. Chem.; 41: 1427-1433.
- Xiaoxia, L.; Lu, Q.; Yongzhe, D.; Lifeng, H.; Erwei, L.; Shiming, F.; Yi, Zh. and Tao, W. (2014). A Review of Recent Research Progress on the Astragalus Genus. Molecules 19: 18850-18880.
- Yun, C.; Lillehoj, H. and Choi, K. (2000). Chicken IFN_{gamma} monoclonal antibodies and their application in Enzyme Linked Immuno Sorbent Assay. Vet. Immuno. Immunopathol, 73: 297-308.
- Zahid, R.; Zafar, I.; Abbas, R. and Ali, R. (2012). Options for Integrated Strategies for the Control of Avian Coccidiosis . International Journal of Agriculture and Biology. 14(6): 1014-1020.
- الزبيدي ، صهيب سعيد علوان . (1986) . إدارة الدواجن . الطبعة الأولى . مطبعة جامعة البصرة .